

Economic Strategies to create a Profit Center with the Edentulous Patient

Dr. Paresh Patel

If I had a nickel for every time a colleague asked me how and why I like doing dentures I would be a rich man! Well it's not so much that I enjoy making dentures, it's that I LOVE making overdentures. With the predictability of implants today I am totally surprised at the sheer number of general dentists who do not invest in improving their bottom line with overdentures. This not only creates a new profit center for long forgotten patients but also improves their life in terms of comfort and confidence for an affordable price. Narrow Diameter Implants (LODI) with a low profile attachment should be considered to help fill this often overlooked set of patients. [Figure 1]



Figure 1

The graying of America has started with over 10,000 people turning 65 each day. These seniors are living longer and more importantly WANT this kind of service. They will actively seek out dentists who offer implants and overdentures under one roof. At our office we place posters and brochures in strategic locations to get our patients to ask about implants along with the teethingplace.com website. [Figure 2]



Figure 2

So why the hesitation for most dentists jumping back into the denture world? Well, most of us remember the dental school days where we spent hours and hours taking impressions, border molding and creating a beautiful almost art like master cast, setting teeth and creating the best denture we could. Even with all this we were often left with a patient that said to us; "This hunk of plastic is terrible!" No wonder most of us abandoned making dentures. There was very little personal satisfaction for us or the patient.

Now enter the world of the overdentures. Add a few implants to help retain that denture and Voilà we now have a happy patient and a totally new revenue stream for our general practice. The best part is that most of these patients will not be insurance driven.

In 2002, the Blair McGill consensus statement strongly suggested that extracting teeth and placing a lower denture could no longer be considered the standard of care. To meet the standard of care 2 standard body implants should be inserted to help retain the lower prosthesis.

Although I agree with the spirit and intent of this consensus, I rarely find in the long-term edentulous patient the necessary width to properly encase a standard body implant without additional surgical procedures (ridge split, bone leveling, grafting). These procedures often are met with resistance from the patient for one of two reasons; financial or medical.

The two implant solution also comes with its own set of potential issues. By design it will always have significant rotation and vertical movement. More importantly the overdenture will become useless if one implant fails. The most elegant treatment to consider, in my opinion, is 4 Narrow Diameter Implants with a proven attachment that has been used worldwide; the LOCATOR. Not only are the rotation issues resolved but 2 additional sites of alveolar bone will be preserved by stimulation from the implant.

Case Report

The patient, a 64-year-old male presented with no lower teeth. [Figure 3] He complained that his lower denture fit well but every time he went to eat it moved around so much that he had adapted to eating better without it. In a recent stay at the hospital he lost the prosthesis. He wanted to replace his missing denture with something that would stay in place better and give him the self confidence to function better in social settings.

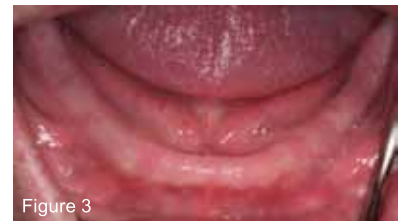

Figure 3

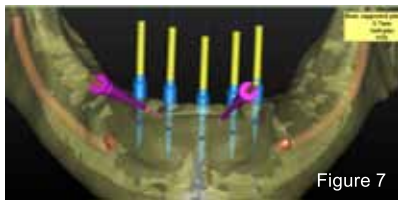
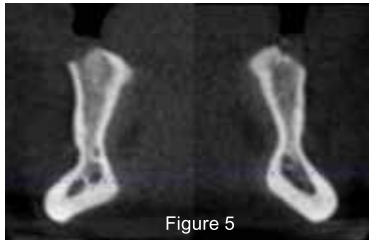
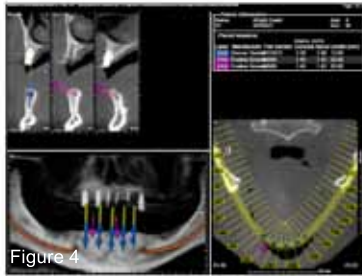He reported that he had been referred to a specialist by his general dentist and declined to move forward at the specialist's office due to the cost of the grafting that was treatment planned in order to have implants placed for an overdenture. The patient specifically sought us out as we offered a different solution to utilize what bone was left.

After a cursory clinical exam I told him I thought his expectations were realistic and his medical history of high blood pressure and diabetes did not preclude him from implant therapy as our approach would be as minimally invasive as possible.

Diagnostic records were taken along with a CBCT scan (iCAT FLX) [Figure 4]. The cone beam scan revealed an irregular ridge pattern in the cross sectional slices [Figure 5]. The anatomy revealed by the CT scan was that of an hourglass shape that would get thinner in the buccal lingual dimension if the ridge was reduced in the hopes of creating enough space for a standard body implant. Without the use of this invaluable technology grave mistakes could have been made in the treatment planning phases.

Based on this information 2.4mm narrow diameter implants with LOCATOR attachments were selected. This size would allow the implant to be rigidly supported by the residual buccal and lingual plates and avoid a ridge split or bone grafting procedure. [figure 6]

A 3D rendering was made and 5 sites were selected [Figure 7]. From the CT scan it could be determined that the bone was of D1 Quality, thus a 1.2mm pilot bit was used to create full length osteotomies with a surgical handpiece. (Aseptic AEU-7000) [Figure 8]. The osteotomies were verified with an endodontic probe to ensure neither the buccal or lingual plate was perforated. The next drill size was used to further open the osteotomies.



The NDI Locator Overdenture implants (LODI) were removed from their sterile containers with the use of the handpiece driver [Figure 9] and fully seated. I like to use the handpiece to place the implant as it helps avoid off axis forces and to take advantage of the self tapping threading. The implants were then fully torqued into place and the LOCATOR attachment was threaded onto the implant to 30ncm to ensure an intimate connection [Figure10].

The Locator comes packaged with the LODI as well as the restorative housing and inserts. With over 45ncm of torque on all 5 implants it was decided to immediately load them. An innovative product (QuickUP) from VOCO was utilized to find where the LOCATOR attachments would rub the inside of the denture [Figure 11].

Once all 5 wells were created in the denture the pink self cure chairside pickup resin was injected to finish the case. Any voids were filled in with the included pink flowable composite material (QuickUP LC) A final CBCT scan was taken on the iCAT FLX to confirm proper implant position [Figure 12].

At the end of the procedure the patient was pleased with the result. Not only were we able to help someone in need but we were able to do it with minimal surgical trauma and cost. A top notch result was delivered that fit the patient's budget and helped improve our practice's bottom line. Narrow Diameter Implants with the Locator attachment are a great resource to consider. With much less height than a standard o-ball attachment the denture can be made more natural feeling and patients appreciate the smooth top. I encourage any surgically oriented general dentist who does not place implants to consider getting the training and offering this service for the patients.

Need Bio

