

# STABILIZING LOOSE DENTURES WITH NARROW DIAMETER IMPLANTS

## CASE PRESENTATION | 3

**A** healthy 55-year-old edentulous male presented with concerns over his loose mandibular complete denture. After having it fabricated, he indicated that he never felt confident in chewing harder foods. He sought out our office because we offer minimally invasive narrow diameter implants to stabilize loose dentures.

Since the patient was interested in having maximum stability for his mandibular denture, a cone-beam CT scan (CBCT) was ordered to determine if bone volume allowed a broad distribution of implant placement. While implants could have been placed without the use of a computerized surgical guide, using a guide ensures precise placement with maximum A-P spread.

A CBCT scan of the patient was made using cotton rolls for occlusal and soft tissue separation, and a radiopaque polyvinyl siloxane (PVS) was applied to the intaglio of the mandibular complete denture. A second scan of the denture was also made and a subsequent dental cast fabricated from the radiopaque PVS impression.

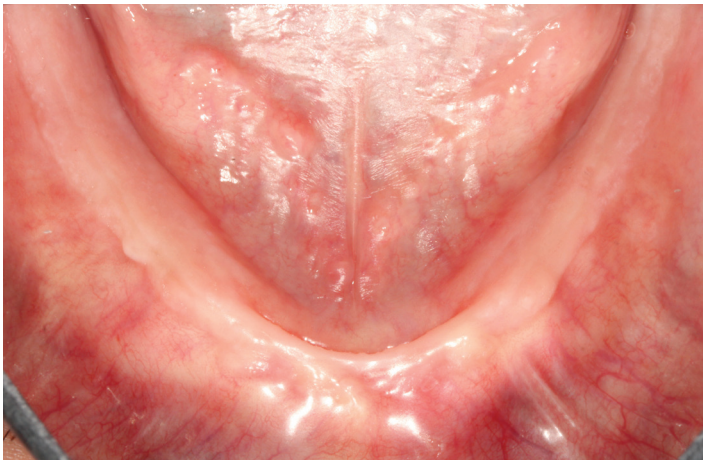
Four 2.9 mm x 12 mm Zest LOCATOR Overdenture Implants (LODI, ZEST Anchors) were planned in the computer software (Invivo, Anatomage) and a guide (Anatomage Guide, Anatomage) was fabricated. Implants were placed using a minimally invasive technique and attached to the denture the same day using an overdenture attachment material (CHAIRSIDE, ZEST Anchors).

When the patient was seen for recall 2 weeks later, the tissues were fully healed. During the 6-month recall, a CBCT scan was made to verify implant healing and integration and to assist in planning additional maxillary implants.

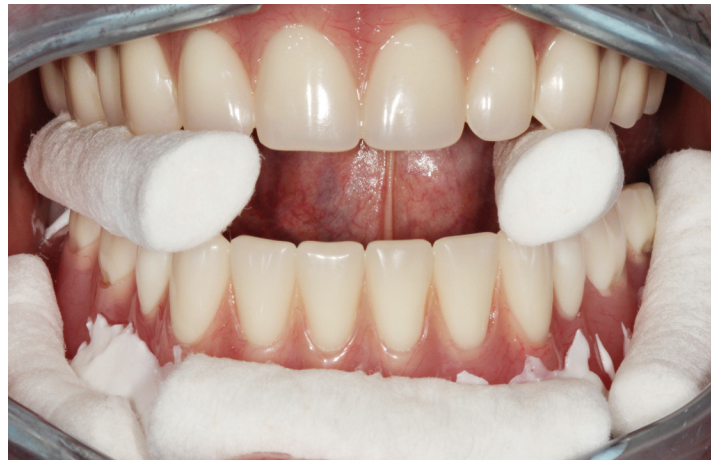**Michael David Scherer,  
DMD, MS, FACP**



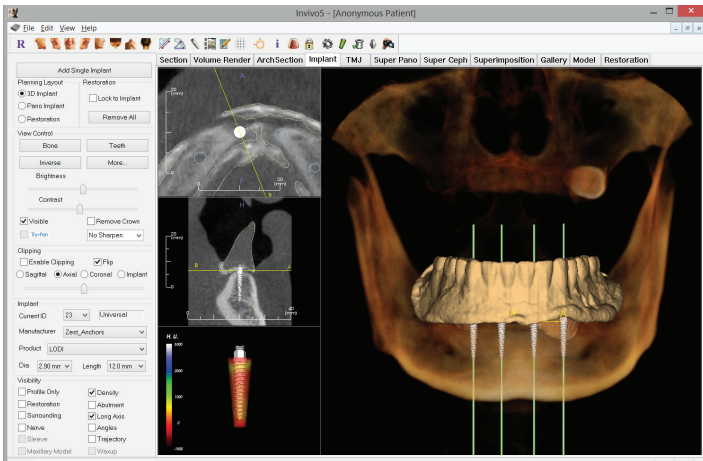
**Michael Scherer, DMD,** is a full-time private practice prosthodontist in Sonora, CA, and an Assistant Clinical Professor at Loma Linda University. He has published articles related to implant dentistry and digital technology with a special emphasis on implant overdentures. Dr. Scherer's involvement in digital implant dentistry has led him to develop and utilize new technology with CAD/CAM surgical systems and outside of the box radiographic imaging concepts.



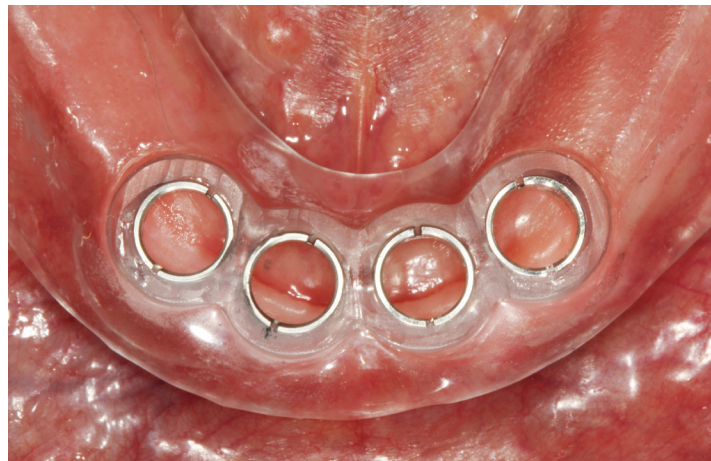
**Figure 1**—Examination of the patient's mandibular ridge shows that he has adequate keratinized soft tissues, firm alveolar support, and adequate prosthetic space for flapless dental implants.



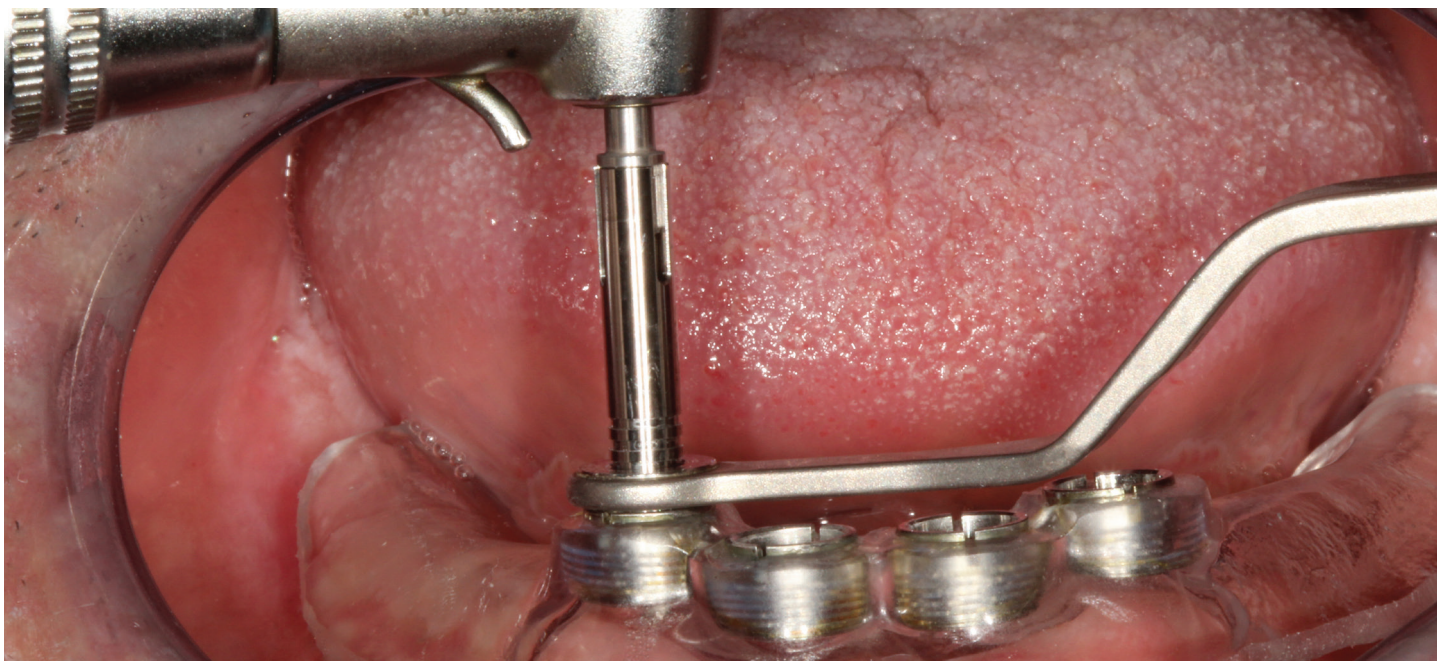**Figure 2**—A radiopaque PVS liner was applied to the intaglio of the mandibular complete denture and a CBCT scan was made with cotton rolls separating the soft tissues and occlusal surfaces of the dentures.



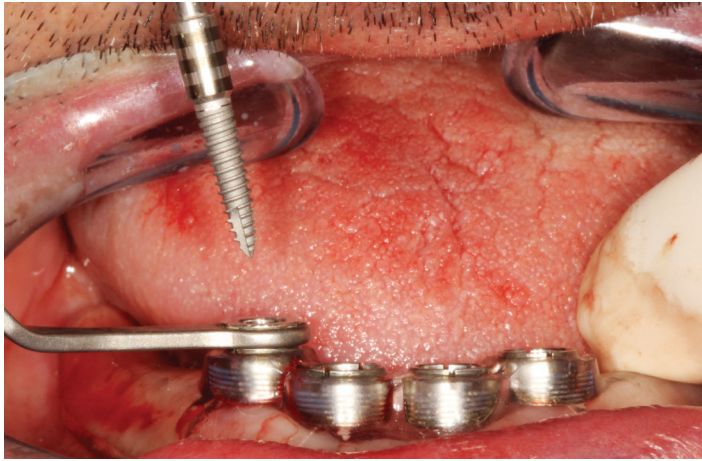
**Figure 3**—Four 2.9 mm x 12 mm LOCATOR overdenture implants (LODI, ZEST Anchors) planned in CBCT software (Invivo, Anatomage).



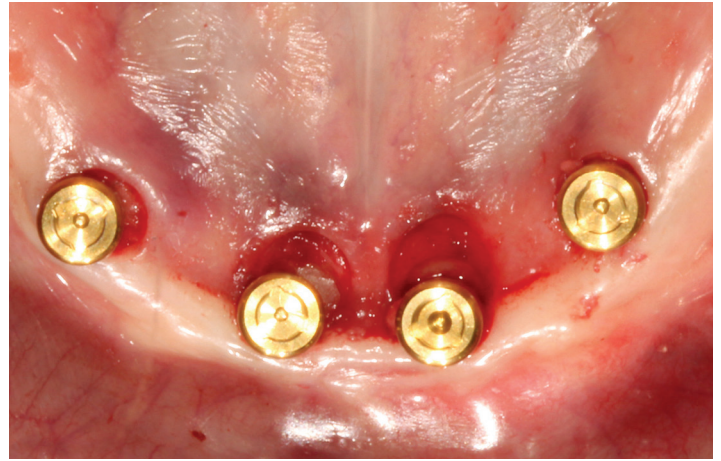
**Figure 4**—Computerized surgical guide tried in the mouth before the surgical appointment, ensuring full tissue adaptation.



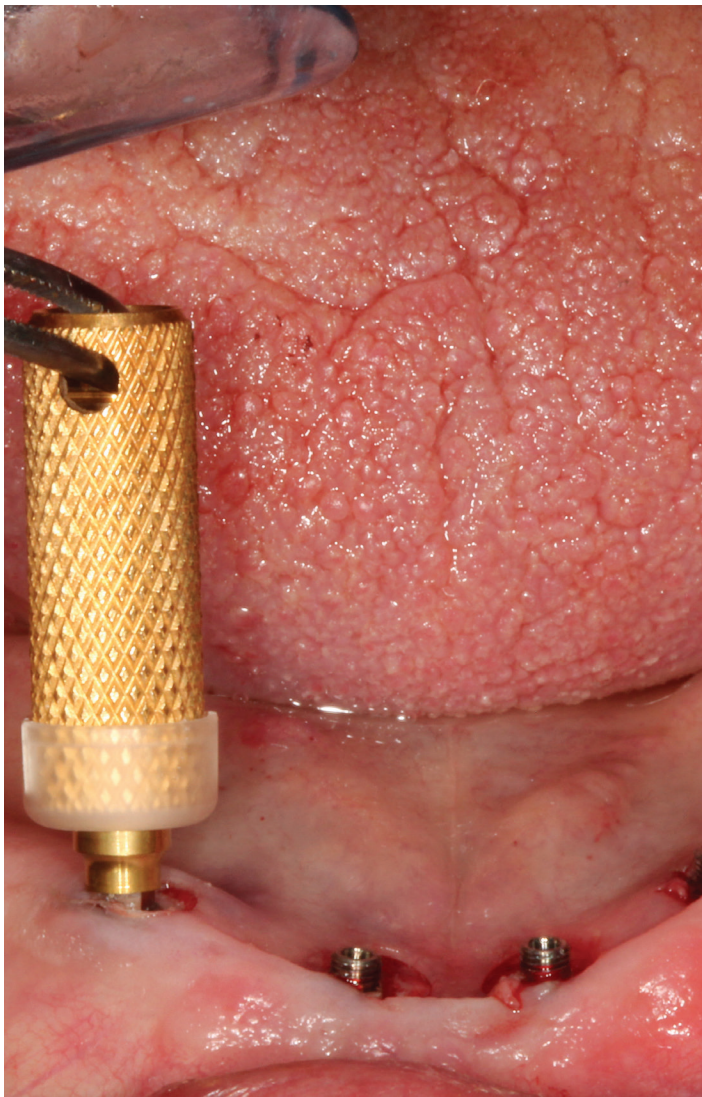**Figure 5**—Sequential osteotomies were prepared with the assistance of the surgical guide, allowing for minimally invasive surgical procedures.



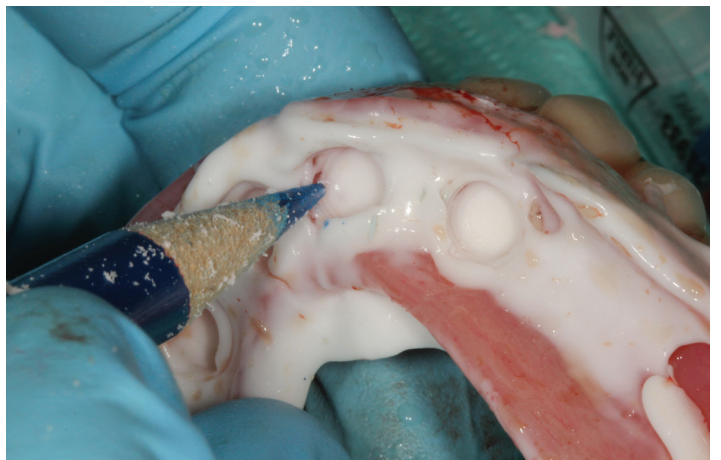**Figure 6**—ZEST LODI implants placed through the surgical guide for maximum precision and alignment of implants.



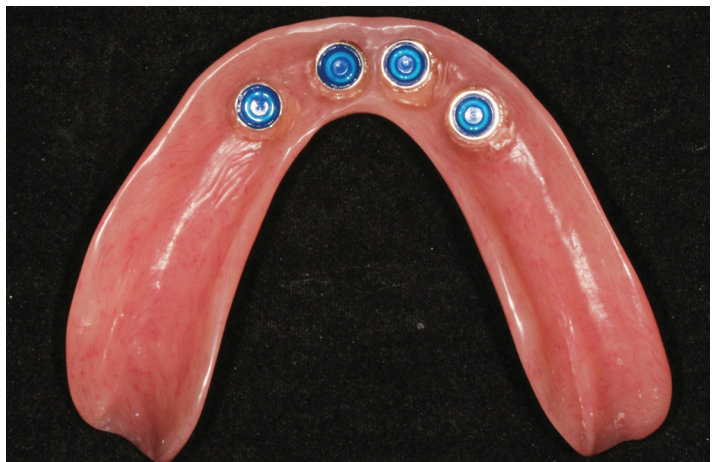**Figure 8**—Immediate postoperative appearance of Zest LODI implants with the LOCATOR attachments, illustrating the desired parallelism of implants for overdentures.



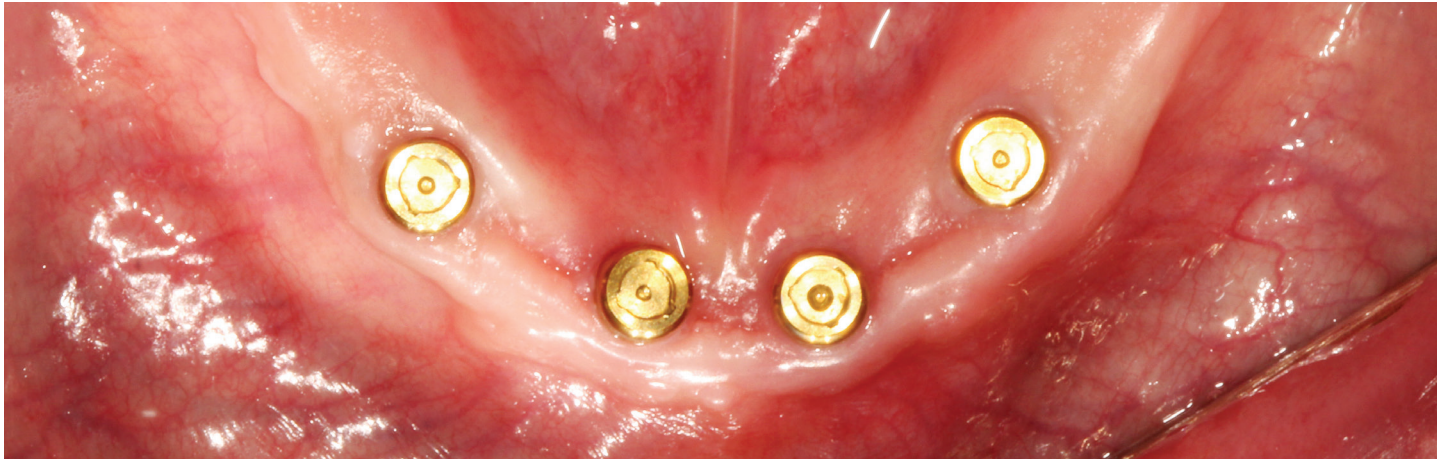
**Figure 7**—ZEST LOCATOR attachments placed onto the LODI implants using the core tool and holder sleeve.



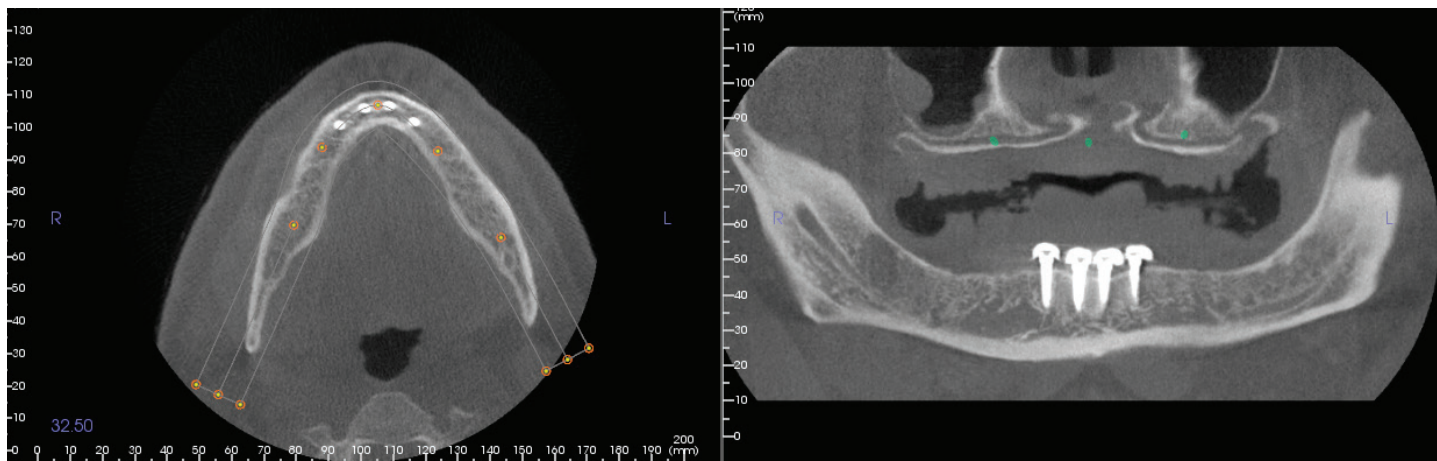
**Figure 9**—Denture caps were placed on the LOCATOR attachments with block-out spacers and PVS used to verify passive fit of the denture over the caps.



**Figure 10**—The denture caps were attached to the denture using an overdenture attachment material (CHAIRSIDE, ZEST Anchors). Processing males were replaced with light nylon inserts and the patient was given postsurgical home-care instructions.



**Figure 11**—The patient was seen 2 weeks after the surgery where complete tissue healing, denture occlusion, and fit of the prosthesis to the implants was verified.



**Figure 12**—During the 6-month recall appointment, a CBCT scan was ordered to assist in planning for additional maxillary implants. This scan allows for visualization of full integration of narrow diameter dental implants.

## GO-TO PRODUCTS USED IN THIS CASE

### CHAIRSIDE ATTACHMENT PROCESSING MATERIAL



CHAIRSIDE is designed for ease of use and predictability when processing attachment components into overdentures.

**ZEST ANCHORS, LLC**  
888.592.9909 ext. 99100  
[www.dps.li/a/4EF-100](http://www.dps.li/a/4EF-100)  
Reader Service 100



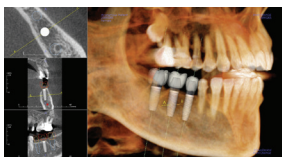
### GREEN-MOUSSE

Green-Mousse provides accuracy, a no-slump consistency, and a choice of setting speeds. It is specially modified for greater flexibility (60-durometer).

**PARKELL, INC**  
888.592.9909 ext. 99263  
[www.dps.li/a/4EF-263](http://www.dps.li/a/4EF-263)  
Reader Service 263

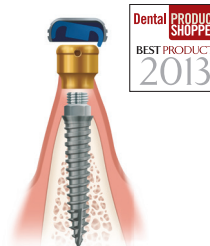

### INVIVO & ANATOMAGE GUIDE



With Invivo 3D imaging software and the Anatomage Surgical Guide, users can add virtual implants, abutments, and restorations and adjust their shape and size.

**ANATOMAGE**  
888.592.9909 ext. 99264  
[www.dps.li/a/4EF-264](http://www.dps.li/a/4EF-264)  
Reader Service 264



### LOCATOR OVERDENTURE IMPLANT (LODI) SYSTEM

The LODI system offers a less invasive, predictable, and cost-conscious technique for securing dentures.

**ZEST ANCHORS, LLC**  
888.592.9909 ext. 99265  
[www.dps.li/a/4EF-265](http://www.dps.li/a/4EF-265)  
Reader Service 265

