

Flap vs. Flapless: a practical guide with indications, recommendations, and techniques for effective planning and surgical placement of narrow diameter overdenture implants in the mandible

Drs. Michael Scherer and Andrew Ingel summarize their rationale on when a flap or a flapless surgical procedure should be performed when placing Zest LODI narrow diameter implant for mandibular overdentures.

Abstract

Implant overdentures are a popular and clinically significant treatment option to present to patients because of the large improvement achieved with a small surgical and financial investment. Narrow diameter overdenture implants, as a result, have gained in popularity in the recent years due to their unique ability to be placed in compromised mandibular alveolar ridges with minimal cost expenditure as osseous grafting may be avoided. Confusion exists, however, in regards to surgical technique for placing these implants. The decision when to elevate a flap or placing the implants with a closed, flapless procedure remains elusive. This article aims to address principles, advantages, disadvantages, and indications of when each procedure is best utilized.

Introduction

The commonly accepted first choice treatment for addressing edentulism is an implant-retained complete denture, commonly known as an overdenture.¹ The placement of two to four dental implants assisting an overdenture prosthesis greatly improves a patient's comfort, masticatory efficiency, and overall quality of life as compared to traditional complete dentures.²⁻⁴ Ongoing residual ridge

Educational aims and objectives

The aim of this article is to review indications, advantages, and disadvantages of flap and flapless surgical procedures for placement of narrow diameter overdenture implants.

Expected outcomes

Correctly answering the questions on page 35, worth 2 hours of CE, will demonstrate the reader can:

- Make an assessment of a patient to determine if implants can be placed flapless or if flap elevation is necessary.
- Recognize the advantages and disadvantages of performing a flap or flapless implant procedure.
- Understand critical steps involved in treatment planning narrow diameter overdenture implants.



resorption can be substantially reduced with the addition of dental implants, allowing for greater ridge height to permit increased stability of a prosthesis.⁵ As the world population ages and the baby boom generation peaks, the rising number of edentulous patients and increasing acceptance of implants dramatically increases the demand for dental implant therapy.⁶

Implant placement can be performed by two methods: flap or flapless. In the flap procedure, surgical access is achieved by making an incision through the gingival tissue down to alveolar bone. After incision, hand instruments are utilized to elevate the tissues away from the bone, giving direct visual access to the surgical

site. Typically, these flaps are performed with full-thickness or periosteal elevating procedures where the bone-tissue periosteum is elevated with the tissue revealing only bone structure underneath. Osteotomies are performed using drills in sequence from smaller to larger diameters, and the implant is placed according to this drill orientation. After the implant is placed, the tissue is re-approximated and closed with sutures. This method of implant placement is the traditional method of dental implant placement because it allows for direct visualization of the bone and is a predictable surgical procedure. A flapped approach is a better approach when either the ridge is very narrow in the buccal/lingual dimension, or there is limited attached gingiva that would be lost using a punch at the crest. Additionally, this also allows the surgeon the ability to reduce height of a knife-edge ridge to develop a crestal table that can accommodate the small diameter implants. The main disadvantage of this technique is the increased amount of surgical morbidity due to an increased amount of surgical access, increased trauma, and increased tissue and bone loss.⁷

Flapless implant surgical procedures are typically performed through the mucosal tissue without elevation of the soft tissue covering the alveolar bone. In this method, osteotomies are performed



Michael Scherer, DMD, MS, is an Assistant Professor in Residence at University of Nevada, Las Vegas (UNLV), an Assistant Clinical Professor at Loma Linda University, and a fellow of the American College of Prosthodontists. He has published articles related to clinical prosthodontics and implant dentistry and completed a master's degree related to implant overdentures with multiple publications pending. Dr. Scherer serves as the director of the implant dentistry curriculum at UNLV and is actively engaged in guided surgical placement and prosthetic restoration of implants.



Andrew Ingel, DMD, received his dental degree from the University of Pittsburgh and completed a GPR at the Hospital of the University of Pennsylvania. He served as an Attending Staff Dentist, Chief of Restorative Dentistry, and Director of the Implant program at the Department of Dental Medicine, Hospital of the University of Pennsylvania and was clinical faculty at the University of Pennsylvania, School of Dental Medicine. Dr. Ingel practiced in the Baltimore-Annapolis area for 17 years prior to moving to Las Vegas where he is an Assistant Professor of Clinical Sciences at the University of Nevada – Las Vegas School of Dental Medicine. Dr. Ingel has interests in both the surgical and restorative aspects of implant dentistry, with a special focus on the clinical applications of small diameter implants.



Krystle Kendall, BS, is currently a senior dental student at University of Nevada, Las Vegas, and has conducted research with published articles in oral cancer, which have been presented at the IADR and ADA annual sessions. Kendall is actively engaged in surgical placement and prosthetic restoration of implants with the co-authors. She is enrolled and will be attending University of Chicago, Illinois, for a prosthodontics residency program.

Disclosure: Dr. Michael Scherer and Dr. Andrew Ingel receive occasional reimbursement for speaking engagements on behalf of Zest Anchors.

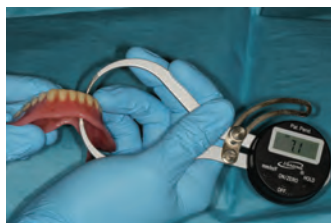

Figure 1: Caliper measurement illustrating sufficient prosthetic space for LOCATOR attachments and housings

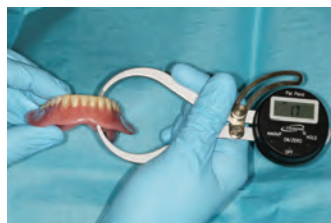

Figure 2: Caliper measurement illustrating insufficient prosthetic space

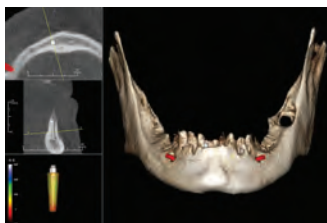


Figure 3: Sharp projections and a narrow anterior ridge require flap procedures to correct poor bone configuration and to ensure implant placement is within bony contours

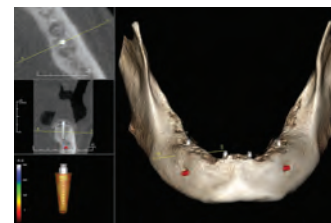


Figure 4: Rounded and U-shaped alveolar ridge allows for flapless implant placement

using drills in sequence from smaller to larger diameter directly through the tissue. In addition to these drills, the clinician may utilize a precision tissue-incising drill, known as a tissue punch. This approach does require an adequate band of attached gingiva that leaves a minimum of 2 mm of attached gingiva on the buccal and lingual following use of the tissue punch. Once osteotomies are completed, an implant is placed through the hole in the tissue and bone, and no sutures are typically needed. The benefits of this approach are largely due to the reduced amount of tissue trauma necessary to place the dental implant. Flapless procedures, however, also tend to be more difficult due to the inability of the surgeon to directly visualize anatomical landmarks and vital structures. The flapless procedure is best suited when a wider ridge and an adequate band of attached gingiva are present. The ridge width can be evaluated when questionable to determine the actual width of the osseous ridge and to rule out thick overlaying tissue that may give the illusion of a wide ridge. Local anesthetic is placed into the soft tissue on both the buccal and lingual; then a periodontal probe is pressed through the gingiva until it contacts the underlying bone. The thickness of the tissue as measured is then added to the thickness of the tissue on the other side of the ridge and then subtracted from the width of the crest to determine the actual width of the osseous crest. These traditional perceived difficulties of flapless procedures can be reduced with the use of cone-beam computed tomography (CBCT) imaging and computerized surgical guides.

Minimally invasive surgical techniques have become an essential part of the dental armamentarium. Routine use of CBCT imaging, along with computer-guided surgical techniques and guides, has given dentists the ability to predictably and reliably place implants through the tissues. Because transmucosal-guided implant placement is typically performed

Table 1: Comparison of flap vs. flapless overdenture implant surgical procedures

	Advantages	Disadvantages
Flapless	<ul style="list-style-type: none"> ✓ Minimal incision and less trauma ✓ Patient comfort ✓ Less bone resorption ✓ Allows for immediate loading ✓ Improved esthetics ✓ Decreased surgical time ✓ Patient perception of "minimally invasive surgery" 	<ul style="list-style-type: none"> – Lack of surgical visibility especially near vital structures – Greater learning curve – Limited irrigation to osteotomy – Limited hard/soft tissue manipulation
Flap	<ul style="list-style-type: none"> ✓ Surgical visibility enhanced ✓ Allows for bone and soft tissue re-contouring ✓ Increased surgical control for osteotomy site selection 	<ul style="list-style-type: none"> – Greater surgical exposure required – Increased postoperative sequelae – Delayed recovery time – Reduced blood supply after flap – Patient perception of "more invasive surgery" – Increased surgical time

without flap elevation, the use of guides also allows for decrease in surgical time, reduced healing times, and increased patient comfort. The development of minimally invasive surgical techniques undoubtedly arose from the disadvantages of a traditional surgical flap approach. The dental profession has largely operated in an outpatient setting, with patients receiving care in an office and returning home to recover. In this setting, dentists are acutely aware of the needs for gentle tissue management, surgical time constraints, and the post-operative complications that many patients endure. The traditional reasons for more extensive flap procedures, such as greater visualization of the surgical site and surrounding anatomy, can be seen as relative disadvantages when considering required surgical time and extent of tissue manipulation. Ultimately, flap procedures have the potential for increased postoperative morbidity, such as swelling and hemorrhage, need for sutures and suture removal, and post-operative pharmaceuticals.

Implant placement of narrow diameter implants is efficiently and readily performed because the size of the implant allows for greater flexibility within narrower alveolar ridges. These narrow ridges may accommodate traditional implant

diameters and lengths but often require extensive bone augmentation procedures, such as ridge splitting or onlay bone grafting. Many patients seek treatment with narrow diameter implants because of the clinician's ability to achieve similar results with a less invasive method.

Criteria for flap vs. flapless surgery

Clinically, the most important first step in assessment of a patient for flapless technique is dependent upon how much prosthetic volume is present with the patient's existing complete denture. One method of assessing this space is to use a caliper to measure a point from inside the intaglio to the occlusal surface of the complete denture. The minimum height requirement needed for a LOCATOR® attachment is 9-11 mm from the crest of the bone to the height of the denture. This breaks down as 1-3 mm soft tissue thickness and a minimum of 3 mm attachment height, including male/female, and 5 mm for overlaying acrylic and teeth of the denture. The denture caliper measurement should be a minimum of 6mm ensuring enough denture material exists to accommodate the attachment and housing complex (LOCATOR, Zest Anchors), which is approximately 3 mm in height (Figure 1). If the caliper measurement

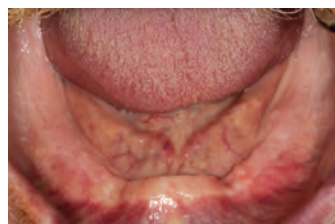


Figure 5: Alveolar ridge examination reveals well-healed, resorbed alveolar ridge with little undercut; ideal candidate for flapless implant placement

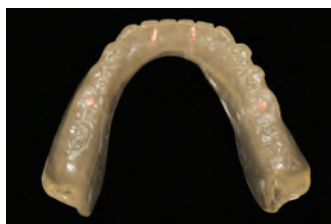

Figure 6: Clear acrylic resin duplicate of the patient's existing complete denture with holes marked with gutta percha to indicate proposed implant sites

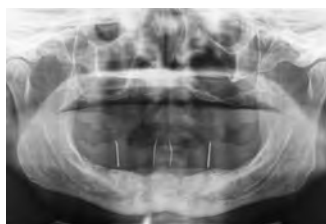


Figure 7: Panoramic radiograph confirms adequate positioning of proposed implant sites

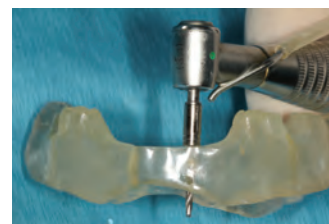

Figure 8: Radiographic guide was modified to create a flat stop for the drill stop, allowing 8 mm of penetration into the mucosa and alveolar bone

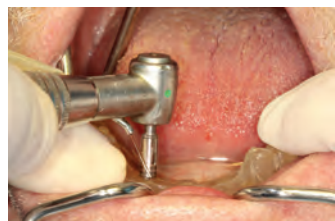

Figure 9: Initial 1.2 mm pilot drill osteotomy performed through the guide

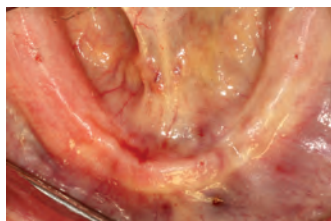


Figure 10: 1.2 mm pilot drill holes indicating proposed implant positions on the ridge

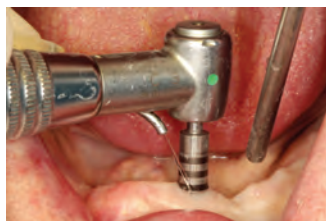

Figure 11: Rotary tissue punch placed into initial osteotomy allows for easy tissue removal

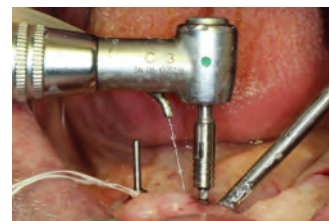

Figure 12: Larger drills (1.6 mm and 2.1 mm) utilized to prepare osteotomy holes using directional indicating pins to ensure implants will be placed parallel to each other

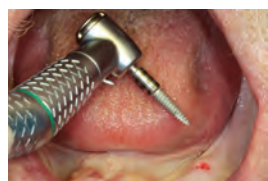

Figure 13: Implant (LODI, Zest Anchors) placed into osteotomy with a handpiece

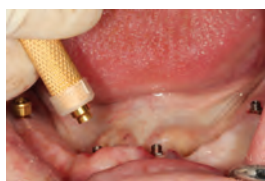

Figure 14: Attachment (LOCATOR, Zest Anchors) placed using LOCATOR core tool and hand-tightened

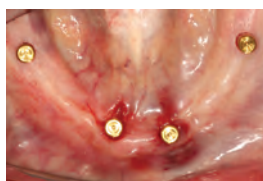

Figure 15: Occlusal view of attachments (LOCATOR, Zest Anchors)

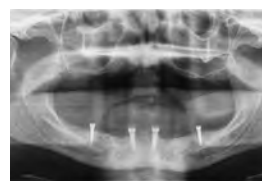

Figure 16: Panoramic radiograph made confirming, verifying proper depth and angulation

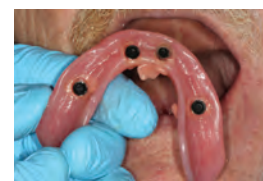

Figure 17: Chairside acrylic resin utilized to intraorally attach LOCATOR housings to denture

is less than 6 mm, insufficient room exists to accommodate the attachment and housing complex, and ridge reduction will be required (Figure 2).

Bone conformation is also an important factor in regards to when a flap procedure is needed. Patients who have had recent extractions within a year typically present with incomplete healing or, in some cases, fractured labial plates from the extraction procedure. Other cases where the bone is very sharp and with shapes that are challenging to place implants can complicate flapless implant surgical procedures (Figure 3). These types of patients will generally require alveolar ridge reduction due to the need for sufficient alveolar bone dimensions surrounding the implant. Patients who present with large, U-shaped, and well-healed alveolar ridges are more favorable for flapless surgical procedures (Figure 4).

Case 1: Narrow diameter overdenture implant flapless placement

A 63-year-old male patient was treated

with traditional tissue-supported complete dentures and was told he was a high-risk candidate for dental implants due to his complex medical history. A few months later, however, he indicated that he never was able to get used to a tissue-supported mandibular denture and indicated that he is seeking a minimally invasive dental implant procedure to help stabilize his denture. Intraoral examination revealed a fully healed atrophic ridge with adequate keratinized soft tissues (Figure 5). To determine if he was a candidate for implant placement, his denture was assessed for adequate prosthetic volume, and a clear acrylic resin replica of his existing complete denture was made (Figure 6). A panoramic radiograph was made with the patient wearing the duplicate denture with gutta percha in drill holes indicating proposed implant sites (Figure 7). A CBCT scan was also performed to further analyze the alveolar ridge conformation, the position of the inferior alveolar nerve, and to better visualize the proposed flapless surgical sites (Figure 4). Four narrow-diameter overdenture implants (LODI, Zest Anchors)

were chosen: 2- 2.9 mm x 12 mm implants in the lateral incisor region and 2- 2.9 mm x 10 mm implants in the mandibular first molar region.

The radiographic guide was modified, converting it to a surgical guide by flattening the area around the proposed implant sites to allow for a flat surface and drill path height of 6 mm. This allowed for the authors to utilize a 14 mm drill stop, knowing the thickness of the guide over the site and the underlying soft tissue for the 1.2 mm pilot drill to penetrate 8 mm into the soft tissue and bone (Figure 8). The guide was placed onto the ridge, and the 1.2 mm pilot with the 14 mm drill stop was drilled through the guide to mark implant osteotomy sites (Figures 9 and 10). Gingival tissue was removed from each site by placing the self-guided rotary tissue punch into the initial osteotomy holes (Figure 11). Osteotomy sites in posterior regions were prepared to 10 mm-depth with 1.2 mm and 1.6 mm diameter drills, and 6-mm depth with the 2.4 mm drill. Osteotomy sites in the anterior region were prepared 12-mm depth with 1.2 mm and 1.6 mm diameter drills, and

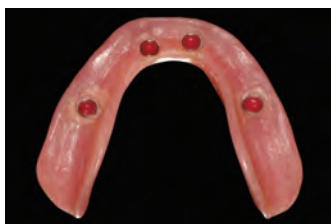

Figure 18: Final intaglio of mandibular complete denture with extra light extended-range LOCATOR male inserts

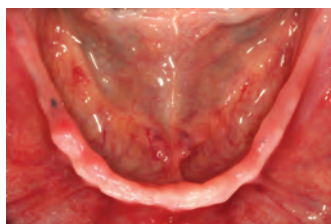

Figure 19: Alveolar ridge examination reveals a narrow and tall alveolar ridge with large undercuts; ideal candidate for traditional flap elevation implant placement

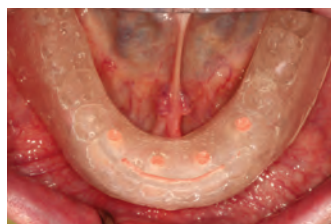

Figure 20: Clear acrylic resin duplicate of the patient's existing complete denture with gutta-percha plugs to indicate proposed implant sites

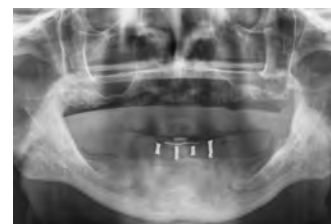

Figure 21: Panoramic radiograph indicates proposed implant positions; excessive vertical bone height is determined

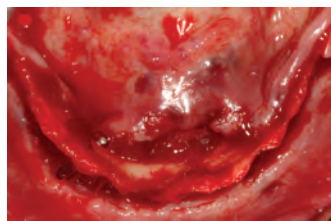

Figure 22: Flap elevation illustrating a sharp, narrow, and undercut alveolar ridge

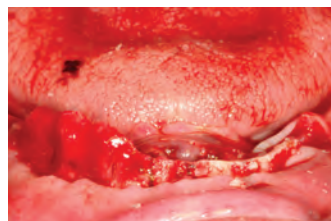

Figure 23: Alveolar reduction performed with proposed implant sites marked with a sterile pencil

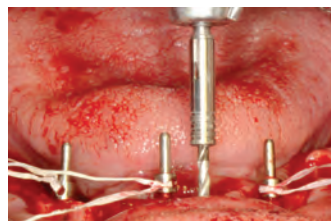


Figure 24: Osteotomies performed with direction indicator pins to ensure parallel implant placement

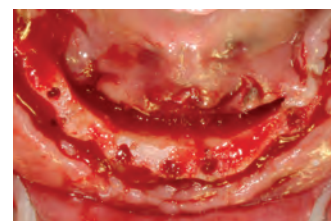

Figure 25: Final osteotomy holes illustrating flexibility of overdenture implants (LODI, Zest Anchors) in extremely narrow ridges

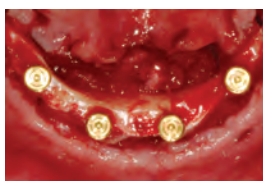

Figure 26: LOCATOR attachments placed, verifying proper angulation and position

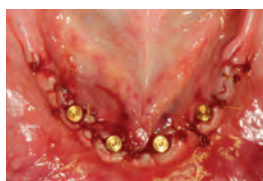

Figure 27: Chromic gut sutures placed, ensuring adequate flap closure with minimal tension

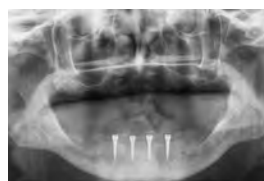

Figure 28: Panoramic radiograph confirms implant position and angulation

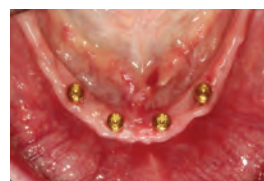

Figure 29: Appearance of alveolar ridge after 2 months of healing

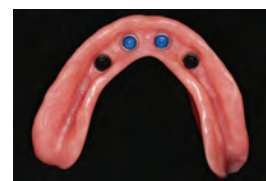

Figure 30: Mandibular complete denture relined to incorporate LOCATOR housings

8-mm depth with 2.4 mm drill. Parallelism of osteotomy sites were verified during the osteotomy procedure, allowing for minor corrections to angulation discrepancies (Figure 12). Two 2.9 mm x 10 mm implants were placed in the posterior osteotomy sites, and two 2.9 mm x 12 mm implants were placed in the anterior osteotomy sites (Figure 13). Final insertion torque values exceeded 35Ncm and was confirmed with the assistance of a manual torque wrench, and 2.5 mm attachments (LOCATOR, Zest Anchors) were placed and hand-tightened on all four implants (Figures 14 and 15). A panoramic radiograph was made to verify implant angulation, depth, and the full seating of the attachments (Figure 16). Since adequate primary stability obtained (> 30N cm) during surgery, the authors decided to immediately attach and load the implants. Should inadequate insertion torque be present, the practitioner can hand-tighten the attachment and place a soft liner inside the denture. The authors recommend if this approach is taken, that the denture be relined over the implants to avoid contact during function

while integration is progressing until a period when the implants can receive the attachments and be activated. The patient's denture was adjusted, attachments (LOCATOR, Zest Anchors) torqued to 30Ncm, and the LOCATOR housings were picked up using chairside hard reline material (Figure 17). The black processing inserts were removed, and an extra-light extended range attachment was inserted into the housings (Figure 18). The patient was re-evaluated weekly and had excellent healing at each appointment. He expressed a tremendous improvement with the stability of his mandibular dentures and a huge improvement in his quality of life.

Case 2: Narrow diameter overdenture implant placement with flap elevation

A 70-year-old male presented with complaints about the fit of his mandibular complete denture and wanted dental implants to provide a more comfortable solution. An examination was performed, and it was determined that he exhibited

an undercut mandibular ridge form with uneven profile that would likely require pre-prosthetic surgery (Figure 19). The patient has seen multiple different dentists seeking a solution and was told each time that he was not a candidate for dental implants because his mandibular ridge is too narrow. A CBCT scan was performed to allow for improved visualization of the alveolar ridge; upon review, the scan confirmed that he would require pre-prosthetic surgical procedures (Figure 3). The authors determined that his existing complete dentures were acceptable; however, insufficient prosthetic space and a sharp alveolar ridge dictated a flap procedure was indicated. The authors estimated that 4-5 mm of alveolar ridge reduction was necessary to ensure sufficient alveolar ridge width and prosthetic space for long-term clinical success.

The patient's existing mandibular denture was duplicated with clear acrylic resin duplicate, and gutta percha was placed in proposed implant sites (Figure 20). A panoramic radiograph confirmed that these proposed sites were acceptable

positions (Figure 21). Four narrow-diameter overdenture implants (LODI, Zest Anchors) were chosen: 4-2.4 mm x 12 mm implants in the lateral incisor and first premolar regions.

Flap elevation was performed with a surgical scalpel and periosteal elevators, reflecting enough tissue facial and lingual to the proposed sites to fully visualize the alveolar ridge contour (Figure 22). Proposed implant sites were marked with a sterile pencil, and approximately 5 mm of alveolar ridge height reduction was performed using surgical acrylic burs (Figure 23). Initial osteotomy sites were prepared to 12 mm depth with 1.2 mm pilot drills using paralleling pins to verify parallelism between the four implants (Figure 24). Final osteotomies were prepared to 8 mm depth with the 1.6 mm drill (Figure 25). Four 2.4 mm x 12 mm implants were placed; insertion torque values exceeded 35Ncm and was confirmed with the assistance of a manual torque wrench, and 2.5 mm LOCATOR attachments placed and torqued to 30Ncm (Figure 26). The tissue was re-approximated, and 3-0 chromic gut sutures were placed using interrupted sutures ensuring minimal tension closure of the flap (Figure 27). A panoramic radiograph was made to verify implant angulation, depth, and the full seating of the attachments (LOCATOR, Zest Anchors) (Figure 28). Even though adequate primary stability obtained (> 30Ncm) during surgery, the authors decided against immediate loading, and a soft tissue liner was applied to the intaglio surface of the denture. Minimal adjustment to the patient's existing denture was required because of the alveolar ridge reduction. The patient was re-evaluated weekly, and at 8 weeks of healing, integration was confirmed with radiographs, percussion, and stability testing (Figure 29). A laboratory relined procedure was performed with the attachments (LOCATOR, Zest Anchors) incorporated into the relined procedure; the authors decided that only the anterior two inserts were needed. During adjustment, the patient noted that he had difficulty removing the denture with all four light attachments, and the patient wished to have less retention (Figure 30). Gray inserts (zero retention) were placed in the distal housings 1 week after the relined procedure. The gray inserts allow the posterior implants to be used as positive tissue stops providing less anterior posterior rotation of the denture. The patient had excellent healing

and expressed a tremendous improvement with the comfort of his mandibular denture.

Discussion

Narrow diameter dental implants were developed as a minimally invasive, low-cost alternative to larger diameter implants. While this implant was intended for use in the stabilization for dentures and as a transitional or salvage approach for failing fixed restorations, it was also intended to be used in immediate function.⁸ Initial insertion stability is achieved by bicortical stabilization between the buccal and lingual osseous plates, and in combination with compressive loading, leads to high levels of initial bone-implant contact.⁹ Since the introduction of implants less than 3 mm in diameter for long-term use, several authors have evaluated the surgical placement technique, immediate loading, denture stabilization, fixed applications, and short and long-term success rates.¹⁰⁻¹² Given the high success rates comparable to larger diameter implants, there has been tremendous interest in narrow diameter implants for both removable and fixed applications. Most systems now feature simplified and minimally invasive surgical protocols, increased patient comfort, improved ability to immediate load, and lower cost.

The cases presented represent typical cases seen by the authors. Based upon the initial exam, both patients are good candidates for denture stabilization utilizing narrow diameter overdenture implants. A rigorous diagnostic evaluation reveals two distinctly different cases requiring different surgical protocols. The first case report presented with a sufficiently resorbed ridge and good prosthetic space. The remaining bone had sufficient width and height as determined by clinical exam and CBCT analysis; this allowed for minimally invasive surgery using a flapless approach and facilitated immediate loading. Post-operative sequelae were minimal with the patient reporting little discomfort. The second case report, however, was deceptive in that width and height were good on clinical and radiographic exam, but the topography of the interforaminal area, as seen on CBCT, was irregular. Using a flapless surgical approach would have presented a substantial surgical challenge. Analysis of the prosthetic space indicated that without bony reduction, the result would have been a prosthetic challenge due to limited room for the attachment

housing in the denture. The surgical protocol included a full-flapped exposure of the implant sites, intra-foraminal bony reduction, implant placement, and suture closure. The denture was not immediately loaded in this case despite good intra-operative torque values.

Conclusion

Proper treatment planning and patient assessment for narrow diameter overdenture implants is a critical step and requires careful pre-operative assessments. Limited information has been previously described when a clinician can place implants using a flapless procedure versus traditional flap elevation. Advantages and disadvantages of flapless and flap surgical procedures were described, including indications of when a flapless procedure can be utilized. The two patients' treatments described represent appropriate examples of when each procedure is indicated. Narrow diameter overdenture implants, such as the Zest Anchors LODI system, are an excellent treatment option for patients with narrow ridges who previously could not get implant therapy and those who wish to have minimally invasive surgical procedures. **IP**

REFERENCES

1. Feine JS, Carlsson GE, Awad MA, Chehade A, Duncan WJ, Gizani S, Head T, Lund JP, MacEntee M, Mericske-Stern R, Mojon P, Morais J, Naert I, Payne AG, Penrod J, Stoker GT Jr, Tawse-Smith A, Taylor TD, Thomason JM, Thomson WM, Wismeijer D. The McGill consensus statement on overdentures. *Int J Prosthodont.* 2002;15:413-414.
2. Toman M, Toksavul S, Saracoglu A, Cura C, Hatipoglu A. Masticatory performance and mandibular movement patterns of patients with natural dentitions, complete dentures, and implant-supported overdentures. *Int J Prosthodont.* 2012;25(2):135-137.
3. Rashid F, Awad MA, Thomason JM, Piovano A, Spielberg GP, Scilingo E, Mojon P, Müller F, Spielberg M, Heydecke G, Stoker G, Wismeijer D, Allen F, Feine JS. The effectiveness of 2-implant overdentures - a pragmatic international multicentre study. *J Oral Rehabil.* 2011;38(3):176-184.
4. Heydecke G, Penrod JR, Takanashi Y, Lund JP, Feine JS, Thomason JM. Cost-effectiveness of mandibular two-implant overdentures and conventional dentures in the edentulous elderly. *J Dent Res.* 2005;84(9):794-799.
5. Kordatzis K, Wright PS, Meijer HJ. Posterior mandibular residual ridge resorption in patients with conventional dentures and implant overdentures. *Int J Oral Maxillofac Implants.* 2003;18(3):447-452.
6. Carlsson GE, Omar R. The future of complete dentures in oral rehabilitation. A critical review. *J Oral Rehabil.* 2010;37(2):143-156.
7. Wood DL, Hoag PM, Donnenfeld OW, Rosenfeld LD. Alveolar crest reduction following full and partial thickness flaps. *J Periodontol.* 1972;43(3):141-144.
8. Sendax VI. Mini-implants as adjuncts for transitional prostheses. *Dent Implantol Update.* 1996;7(2):12-15.
9. Sendax, V. *Mini Dental Implants: Principles and Practice.* St. Louis, Mo: Elsevier/Mosby; 2013.
10. Bulard RA, Vance JB. Multi-clinic evaluation using mini-dental implants for long-term denture stabilization: a preliminary biometric evaluation. *Compend Contin Educ Dent.* 2005;26(12):892-897.
11. Ahn MR, An KM, Choi JH, Sohn DS. Immediate loading with mini dental implants in the fully edentulous mandible. *Implant Dent.* 2004;13(4):367-372.
12. Balkin BE, Steffik DE, Naval F. Mini-dental implant insertion with the auto-advance technique for ongoing applications. *J Oral Implantol.* 2001;27(1):32-37.