



Nadim Z. Baba, DMD, MSD

Professor and Director, Hugh Love Center for Research and Education in Technology, Loma Linda University School of Dentistry, Loma Linda, California; Private Practice, Glendale, California

Rehabilitation of a Failing Maxillary Arch

With the use of an implant-supported overdenture retained by Locator R-Tx™ abutments

A 91-year-old male patient presented for a specialist consultation complaining of a loose maxillary fixed partial denture (FPD). The FPD was supported by an implant in position No. 4 and two natural teeth, Nos. 7 and 8, which were nonrestorable with severe decay. On the left side two implants, Nos. 11 and 12, held an implant-supported FPD with a cantilever on tooth No. 10. Implant No. 13 had an implant-supported crown. After several treatment modalities were reviewed with the patient, he opted for an implant-supported overdenture (ISO). Because of financial limitations and dexterity issues, three implants were used instead of the four remaining in the maxilla, which would make it easier for the patient to remove the denture. Retained using Locator R-Tx™ abutments (ZEST Anchors, www.zestanchors.com), the maxillary ISO proved highly retentive despite severe divergence between the implants. As demonstrated, the Locator R-Tx abutment offers an excellent service to both patients and their treating dentists.

KEY TAKEAWAYS

- Locator R-Tx abutments were used to retain both the immediate denture and the implant-supported overdenture.
- Convenient all-in-one double-ended vial packaging contained all required components, including the R-Tx abutment, denture attachment housing, block-out spacer, and four retention inserts.
- The Locator R-Tx abutment demonstrated superiority to the traditional Locator by allowing more divergence between implants.

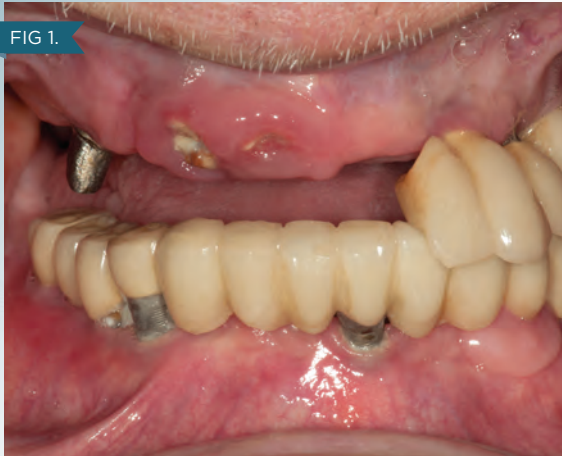

FIG 1. Frontal view of patient, a 91-year-old man who lost his maxillary FPD, showing the nonrestorable root remnants of the upper left canine and lateral. Implant No. 4 had a custom abutment screwed to the implant. Given his medical history, age, and financial limitations, the patient decided to have all the remaining implant-supported FPDs and crowns removed and receive an ISO retained by three Locator R-Tx abutments.




FIG 2. Locator R-Tx abutment.

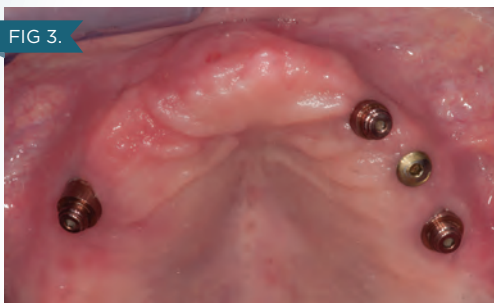

FIG 3. Occlusal view of the Locator R-Tx abutments on implants Nos. 4, 11, and 13. A cover screw was placed on implant No. 12. The Locator R-Tx abutments would be used to retain both the immediate denture and the ISO.

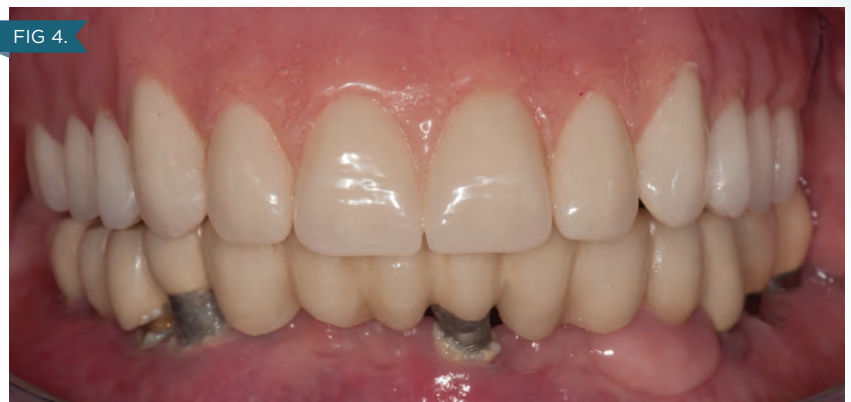

FIG 4. An immediate complete denture was delivered after the extraction of teeth remnants Nos. 6 and 7 and the removal of all remaining implant-supported FPDs and crowns.

FIG 5. Locator R-Tx impression copings were securely positioned on the Locator R-Tx abutments Nos. 4, 11, and 13.

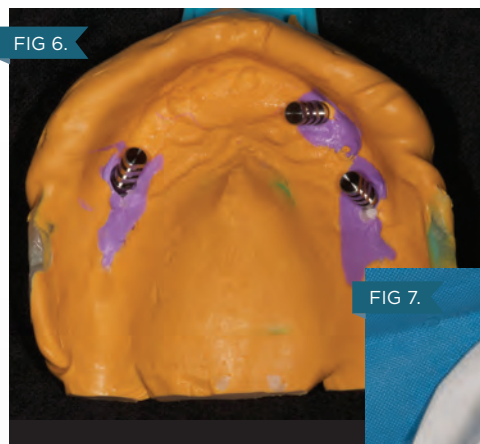
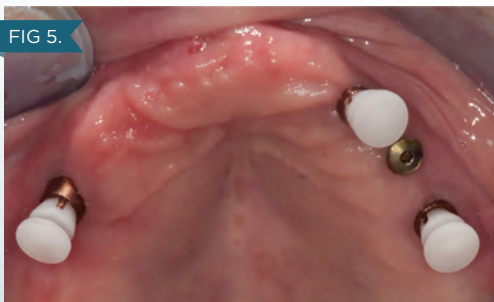

FIG 6.

FIG 6. Maxillary definitive impression with Locator R-Tx abutment analogues attached to the picked-up impression copings. **FIG 7.** Maxillary definitive cast with locator R-Tx abutment analogues. After virtual design of the metal framework for the ISO was done and printed resin pattern was made ready to invest and cast, wax rims were added to the removable partial denture framework (shown here), tried in the patient's mouth and adjusted, and an interocclusal record was made.

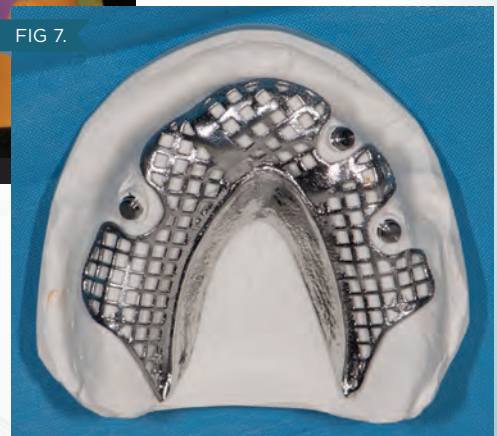

FIG 7.

FIG 8.

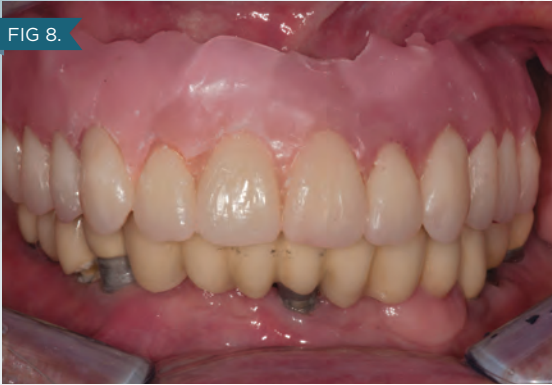

FIG 8. After the cast was mounted on a semi-adjustable articulator, the teeth were set up and tried in the patient's mouth to assess phonetics and esthetics and obtain patient approval.

FIG 9.

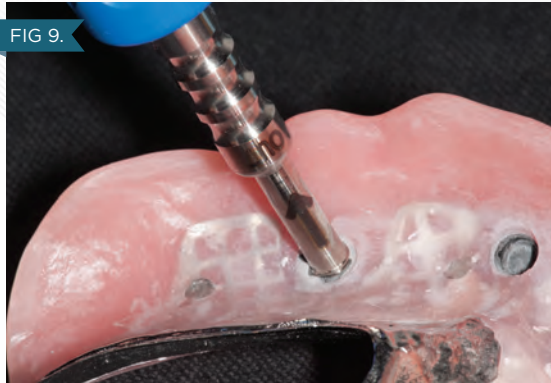

FIG 9. After processing of the ISO, the Locator R-Tx retention insert tool was used to remove the black processing inserts from the denture attachment housings in the definitive ISO.

FIG 10.

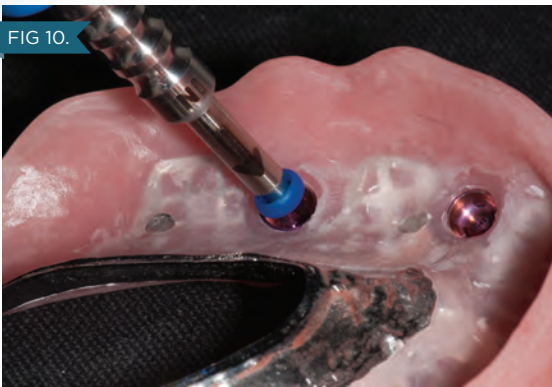

FIG 10. After a grinding bur from the Chairside® Denture Prep & Polish Kit (ZEST Anchors) was used to remove the excess of acrylic around the denture attachment housing, the retention insert tool was used to place the low-retention insert in the denture attachment housings (shown here). To facilitate the removal and insertion of the definitive overdenture, a low-retention insert and two zero-retention inserts would be placed in the denture attachment housings.

FIG 11.

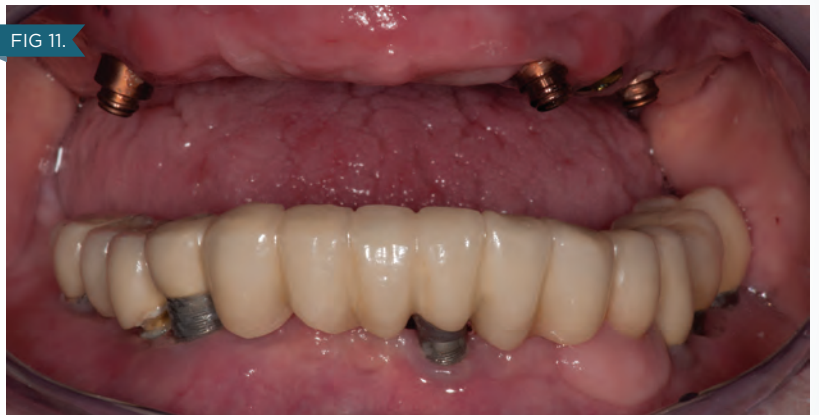

FIG 11. Frontal view showing the severe divergence between the abutments. Despite the severe divergence, the definitive denture was very retentive.

FIG 12.

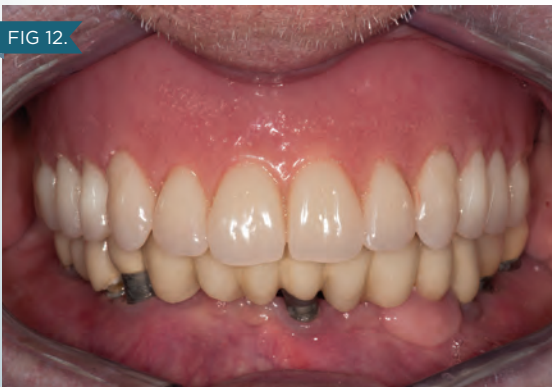

FIG 12. Frontal view of the definitive ISO.

FIG 13.

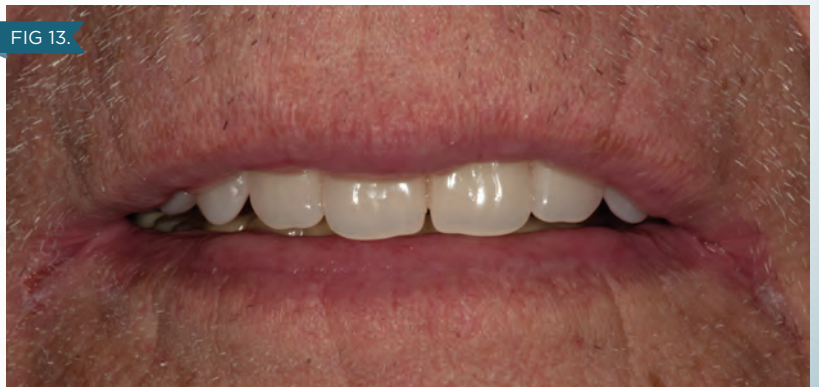

FIG 13. Esthetic appearance of the definitive ISO.